Check for updates

Received: 27 April 2023 | Revised: 9 May 2023 | Accepted: 10 May 2023

DOI: 10.1111/jne.13306

CLINICAL GUIDELINE

Journal of Neuroendocrinology WILEY

European Neuroendocrine Tumor Society (ENETS) 2023 guidance paper for gastroduodenal neuroendocrine tumours (NETs) G1–G3

Francesco Panzuto[1] | John Ramage[2] | D. Mark Pritchard[3] | Marie-Louise F. van Velthuysen[4] | Joerg Schrader[5] | Nehara Begum[6] | Anders Sundin[7] | Massimo Falconi[8] | Dermot O'Toole[9]

[1]Department of Medical-Surgical Sciences and Translational Medicine, Digestive Disease Unit, Sant'Andrea University Hospital, ENETS Center of Excellence, Sapienza University of Rome, Rome, Italy

[2]Department of Gastroenterology, Hampshire Hospitals and ENETS Center, Kings Health Partners London, London, United Kingdom

[3]Department of Molecular and Clinical Cancer Medicine, University of Liverpool, Liverpool, UK

[4]Department of Pathology, Erasmus MC, University Medical Center Rotterdam, Rotterdam, The Netherlands

[5]Department of Medicine, University Medical Center Hamburg-Eppendorf, Hamburg, Germany

[6]Department for General-, Visceral-, Thoracic- and Endocrine Surgery, Johannes-Wesling-Klinikum Minden, University Hospital of the Ruhr-University Bochum, Bochum, Germany

[7]Department of Surgical Sciences, Radiology & Molecular Imaging, Uppsala University, Uppsala, Sweden

[8]Pancreas Translational and Clinical Research Center, Pancreatic Surgery Unit, IRCCS San Raffaele Scientific Institute, Milan, Italy

[9]National Centre for Neuroendocrine Tumours, ENETS Centre of Excellence, St. Vincent's University Hospital, Dublin, Ireland

Correspondence
Francesco Panzuto, Department of Medical-Surgical Sciences and Translational Medicine, Digestive Disease Unit, Sant'Andrea University Hospital, ENETS Center of Excellence, Sapienza University of Rome, via di Grottarossa 1035, 00189 Rome, Italy.
Email: francesco.panzuto@uniroma1.it

Abstract

The aim of the present guidance paper was to update the previous ENETS guidelines on well-differentiated gastric and duodenal neuroendocrine tumours (NETs), providing practical guidance for specialists in the diagnosis and management of gastroduodenal NETs. Type II gastric NETs, neuroendocrine carcinomas (NECs), and functioning duodenal NETs are not covered, since they will be discussed in other ENETS guidance papers.

KEYWORDS
duodenal neuroendocrine tumours, gastric carcinoids, guidelines, management, prognosis

1 | GASTRIC NEUROENDOCRINE TUMOURS

1.1 | Introduction – general background

Gastric neuroendocrine neoplasms (gNENs) are rare tumours with an increasing annual incidence of ~0.4/100,000, and a prevalence of 3/100,000.[1] The vast majority of gNENs are well-differentiated neuroendrocrine tumours (NETs), which are usually classified according to the background gastric pathology into three major categories: (i) type I when chronic atrophic gastritis (CAG) is present resulting in hypergastrinaemia (the most common type, accounting for 75%–80% of all gNENs); (ii) type II when the tumour occurs due to hypergastrinaemia in the context of Zollinger–Ellison syndrome (ZES) and

This is an open access article under the terms of the Creative Commons Attribution-NonCommercial-NoDerivs License, which permits use and distribution in any medium, provided the original work is properly cited, the use is non-commercial and no modifications or adaptations are made.
© 2023 The Authors. *Journal of Neuroendocrinology* published by John Wiley & Sons Ltd on behalf of British Society for Neuroendocrinology.

multiple endocrine neoplasia type I (MEN-I) syndrome (5% of gNENs); type III, which are sporadic lesions not associated with hypergastrinaemia (15%–25% of gNENs). Type I gNETs are indolent, with negligible risk of metastases (<5%) and excellent long-term survival (almost 100%); the prognosis of a patient with type II gNETs needs to be assessed in the context of MEN-I syndrome; however, the risk of metastases may vary between 10% and 30%. Type III tumours are usually more aggressive, owing to the high prevalence of metastatic disease (>50%) and the more unfavourable long-term survival (5-year survival rate 70%), although they present well-differentiated morphology in the majority of cases. Type III gNENs may also have higher grades. The key questions discussed in the present paper are summarised in Table 1. Data were identified by MEDLINE database searches and expert opinion/recommendations given according to the best available evidence and the authors' experience. Each recommendation for treatment and diagnosis will have a level of evidence and grade of recommendation as per the GRADE system (Table S1). The major features of gNETs are summarised in Table 2.

TABLE 1 List of questions.

GASTRIC NET
Q1 – What is the role of endoscopic resection for type I gNETs? Is additional treatment required in cases of R1 endoscopic resection?
Q2 – When should somatostatin analogues be used to treat type I gNETs?
Q3 – What is the recommended follow-up schedule in type I gNETs?
Q4 – When is surgery recommended for type I gNETs?
Q5 – Can endoscopic treatments be proposed to treat type III gNETs?
Q6 – When should limited or extended surgical treatments be proposed to treat type III gNETs?
Q7 – What scheduled follow-up is recommended after endoscopic/surgical resection of type III gNETs?
DUODENAL NET
Q8 – When is endoscopic resection indicated?
Q9 – Can a "watch and wait" strategy be proposed in dNETs?
Q10 – When is surgery indicated?

1.2 | Assessment of gastric neuroendocrine tumours

1.2.1 | Pathology

Gastric neuroendocrine tumours (gNETs) are different from other gastrointestinal NETs as in the stomach a clear aetiology is emerging where gastric NETs are induced in the context of hyperplasia of enterochromaffin-like (ECL) cells. In 1993 an aetiological framework for gastric NETs was reported,[2] where gastric NETs were either found in a setting of ECL cell hyperplasia associated with high gastrin levels due to autoimmune fundic atrophic gastritis (type I NETs), high gastrin levels due to gastrinoma (type II NETs) or without ECL hyperplasia (type III NETs). More recently, general atrophy in chronic *H. pylori* associated gastritis,[3] functional failure of parietal cells due to mutations[4] or proton pump inhibitor (PPI) use[5] have also been reported to be associated with NETs, some with a background of ECL cell hyperplasia but in cases of proton pump inhibition also associated with parietal cell hyperplasia. These newly described gastric NETs are similar to the originally described type I gNETs as they are secondary to failed acid secretion. The secondary (type I and type II) gNETs have a more indolent course[2,5] and can be reversible if the cause can be impeded. It is therefore important to recognise the associated gastric mucosal changes.[6]

Adequate tumour sampling is essential for grading NETs as prescribed in the World Health Organization (WHO) classification of gastrointestinal tumours of 2019.[7] As NETs are usually located deep in the mucosa (not at the surface) attention should be paid to this when taking biopsies.

Gastric NETs are graded using the same criteria as for all gastrointestinal sites:[8]

G1: mitotic count <2 in 2 mm^2 and/or Ki-67 index <3% in hotspot of at least 500 cells.

G2: mitotic count between 2 and 20 in 2 mm^2 and/or Ki-67 index between 3% and 20% in hotspot of at least 500 cells.

G3: mitotic count >20 in 2 mm^2 and/or Ki-67 index >20% in hotspot of at least 500 cells.

1.2.2 | Endoscopy

The primary diagnostic tool for gNETs is oesophagogastroduodenoscopy (OGD). For the assessment of gastric NETs, not only representative biopsies of the tumour but also biopsies of the surrounding mucosa and other parts of the stomach (antrum and body-fundus) are essential as these give clues on the nature/aetiology and, with this, the prognosis and treatment of the NET. In addition, sampling of gastric juice for pH measurement is strongly encouraged. Furthermore, virtual chromoendoscopy (narrow-band imaging, blue light imaging, i-scan) may be useful to provide additional information to identify field changes or precancerous lesions in underlying atrophic mucosa.[9] In addition to OGD, endoscopic ultrasound (EUS) should be performed in all lesions >1 cm regardless of type and in all lesions of type III regardless of size, unless large or metastatic lesions are found. Reporting should include size of the lesion infiltration depth and assessment of local lymph nodes.

Recommendations

Evaluation of gNETs should always include:

1. Biopsies to evaluate proliferative activity of the tumour (Ki67 and/or mitotic count) for grading (2b-A).

13652826, 2023, 8, Downloaded from https://onlinelibrary.wiley.com/doi/10.1111/jne.13306, Wiley Online Library on [13/08/2025]. See the Terms and Conditions (https://onlinelibrary.wiley.com/terms-and-conditions) on Wiley Online Library for rules of use; OA articles are governed by the applicable Creative Commons License

TABLE 2 Diagnostic criteria and prognosis of gNET subtypes.

Type	Gastric pH	Histology of surrounding mucosa	Gastrin levels	Grading	Prognosis
I	High	Gastric body atrophy, ECL-cell hyperplasia	High	G1 (G2)	Excellent: Risk of metastases very low. In general, normal life expectancy
II	Low	ECL-cell hyperplasia	High	(G1) G2	Unclear due to lack of data: Overall survival likely to be defined by underlying MEN1 syndrome
III	Normal	Normal	Normal	G2/G3	Poor: Risk of metastases high. Overall survival compromised except for early stages.

Abbreviation: ECL, enterochromaffin-like; gNET, gastric neuroendocrine tumour.

2. Evaluation of the type of gNET by assessing separate biopsies from the antral and fundic mucosa (2b-A).
3. EUS is recommended in tumours >1 cm (3b-B).

1.2.3 | Imaging and laboratory examinations

Biomarker assessment should include fasting gastrin and chromogranin A (CgA). Whereas gastrin may be useful to differentiate between different types (elevated in type I and type II, normal in type III), CgA is only useful as a tumour marker in type III gNETs. In the presence of ongoing PPI therapy gastrin and CgA are not diagnostic and are difficult to interpret. In general, caution should be used when evaluating CgA values, considering the different diagnostic accuracy of available assays. Parietal cell and intrinsic factor antibodies, vitamin B12 and thyroid function parameters should be measured in suspected cases of autoimmune gastritis.

Whereas type I gNETs do not usually require additional cross-sectional imaging, type III gNETs should undergo cross-sectional imaging – liver contrast-enhanced magnetic resonance imaging (MRI) and/or contrast-enhanced thoracoabdominal computed tomography (CT), with previous ingestion of water immediately before examination, to fill stomach and duodenum and better depict small enhancing lesion in the arterial phase, and functional imaging, preferentially somatostatin receptor PET/CT (^{68}Ga-SSA-PET-CT).

These should also be considered in cases of type I gNETs with metastases on EUS or high-risk features of metastases (G2, lymphatic or vascular invasion, size ≥1 cm). Recently, ^{68}Ga-SSA-PET-CT has been suggested in selected cases with tumour diameter >1 cm, G2 tumours (perhaps Ki-67 > 10 but exact cutoff not determined), or R1 margins after endoscopic resection.[10]

Prognosis depends on type, size, grading, histological risk factors (e.g., lymphovascular invasion, perineural invasion), completeness of resection and initial tumour stage.

Recommendations

1. Gastrin assessment is useful to differentiate between different types of gNETs. CgA is useful as tumour marker only in type III gNETs (3b-A).
2. Cross-sectional radiological imaging (CT/MRI) and ^{68}Ga-SSA-PET-CT are not required in type I gNETs, unless metastases on EUS or in the presence of high-risk features (G2, vessel invasion, suspected T2 on EUS) (3b–A).

1.3 | Management strategy for type I gNETs

1.3.1 | Introduction

Treatment options for type I gNETs include surveillance, endoscopic resection, somatostatin analogues (SSA) and eventually surgery. As prognosis is usually quite favourable and tumour growth slow and risk of metastases is below 1% in tumours <10 mm, all NET <1 cm can be observed without any need for intervention.[11,12] The ideal schedule for observational OGD is not defined and clinical practice ranges from every 6 months to every 2 years. Planning the first follow-up after 6 months and then every 12 months is the most widely used approach. A regular rebiopsy of lesions is not necessary unless atypical features (e.g., ulceration, erosion, pitting) appear, suggesting invasive progression of the lesion. The management of type I gNETs is summarised in Figure 1.

1.3.2 | Q1 – What is the role of endoscopic resection for type I gNETs? Is additional treatment required in cases of R1 endoscopic resection?

Endoscopic resection should be considered for type I gNETs larger than 1 cm and for those lesions demonstrating increased Ki-67 as these features are associated with an increased risk of metastases and progression.[11,13] Many small type I gNETs are G1 or low G2 (Ki-67 < 10%);[14] however, a Ki-67 cutoff has not been defined to determined when excision should be performed. Endoscopic ultrasonography to determine depth of local invasion and assessment of local lymph nodes should be performed in lesions >1 cm and in smaller tumours with "high" G2 grade (cutoff not established) before any resection. No other imaging modality is required at this stage. The resection technique of choice depends on size and position of the lesion, invasion depth and local experience. Endoscopic mucosal resection (EMR), endoscopic submucosal dissection (ESD) and full-thickness resection (FTR) are all associated with a low risk profile for both bleeding and perforation. It is not clear which is the best endoscopic technique to be used for achieving a complete R0 resection.[15] However, resection by ESD or FTR achieve higher rates of R0 resection, but no randomised trials have compared all techniques head-to-head.[16,17] For R1 resection status a re-resection in a "step-up" approach could be recommended (e.g., ESD after EMR, FTR after ESD), although data showing risk of local recurrence after R1

13652826, 2023, 8, Downloaded from https://onlinelibrary.wiley.com/doi/10.1111/jne.13306, Wiley Online Library on [13/08/2025]. See the Terms and Conditions (https://onlinelibrary.wiley.com/terms-and-conditions) on Wiley Online Library for rules of use; OA articles are governed by the applicable Creative Commons License

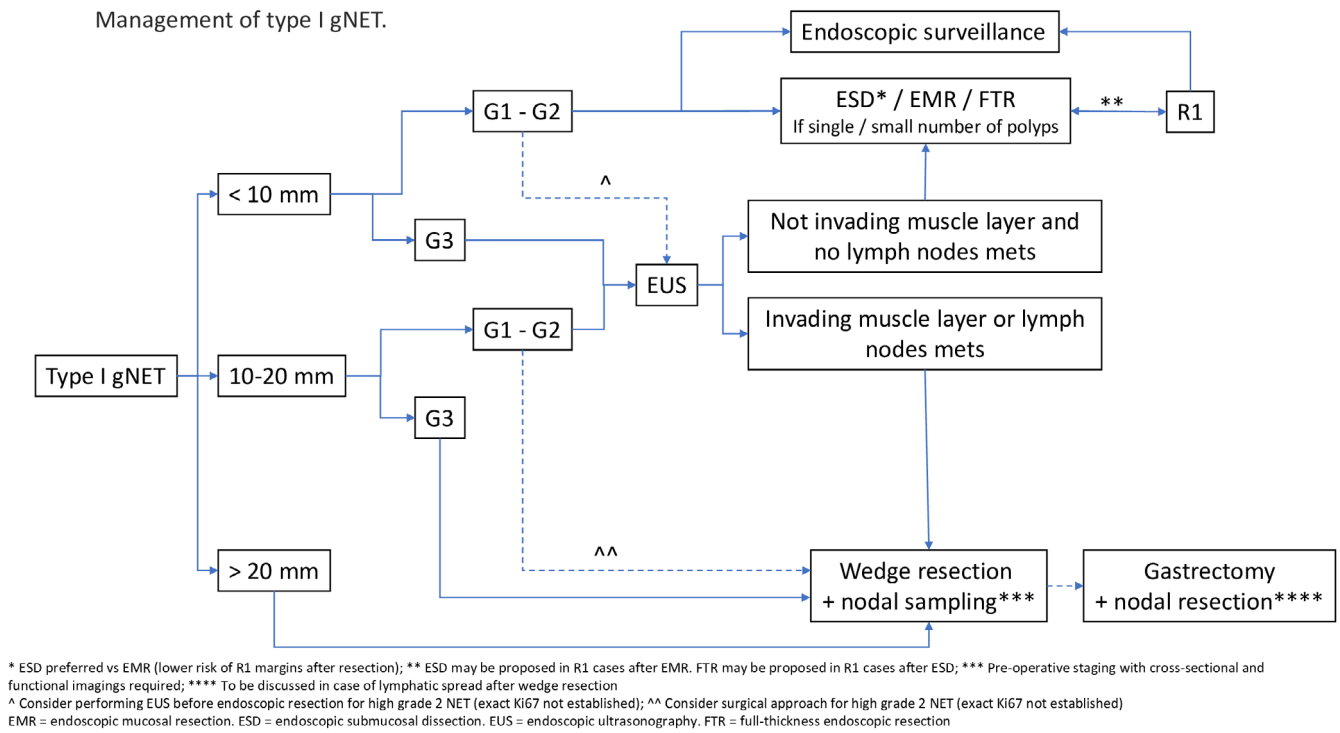

FIGURE 1 Management of type I gastric neuroendocrine tumours (gNETs).

resection are scarce,[18] particularly for smaller tumours which may be managed by a non-interventional endoscopic surveillance after initial R1 resection.[19]

Conclusion/recommendations

1. Endoscopic resection should be proposed in type I gNETs larger than 1 cm (2b-A).
2. ESD and FTR are more effective to achieve R0 resection compared to EMR (2b-B).
3. In case of incomplete resection (R1) of a NET >1 cm a step-up approach (EMR > ESD > FTR > surgery) is recommended (4-C).

1.3.3 | Q2 – When should somatostatin analogues be used to treat type I gNETs?

Type I gNETs usually express somatostatin receptors. Thus, therapy with SSA can be initiated in metastasised patients or patients not amenable to endoscopic or surgical resection (e.g., difficult location, old age, comorbidities). SSA therapy is associated with a high complete response rate of 25%–100%, but relapse is frequently observed after discontinuation of therapy.[20] Thus, continuous therapy would be the appropriate approach. Another reason for starting SSA therapy could be large tumour size or the requirement of repeated endoscopic resection for progressive lesions, although data evaluating this approach are lacking. Another therapeutic approach could be direct inhibition of gastrin signalling in tumour cells. Indeed, the gastrin receptor inhibitor netazepide has been evaluated in a proof-of-concept phase II trial with 16 patients showing a complete response rate in 30% of patients.[21] Like SSA treatment, tumour relapse after discontinuation was observed in all patients. The clinical benefit of netazepide needs to be evaluated in larger randomised clinical trials before any recommendation for its use can be formulated.

Recommendations

1. In type I gNET patients when tumour resection is indicated but endoscopic or surgical techniques are not possible, SSA therapy is appropriate (2b-A).

1.3.4 | Q3 – What is the recommended follow-up schedule in type I gNETs?

An endoscopic follow-up every 12 months is recommended after complete endoscopic resection of a type I gNET. Whether this interval can be increased after prolonged periods without evidence of relapse or whether the interval should be shortened in case of incomplete (R1) resection or risk factors associated with progression (grading G2, size >20 mm) should be carefully discussed with the patient. In general, no cross-sectional imaging is required for follow-up. In addition, repeated evaluation of biomarkers CgA and gastrin should not be performed as these markers are elevated due to the underlying CAG and are not an indicator of relapse or progression. Follow-up OGD is recommended in a type I gNET that does not require resection, although the optimal interval for planning endoscopy is not established (1–2 years can be considered, following first follow-up 6–12 months after initial diagnosis). Apart from risk of tumour progression or relapse after resection in NET lesions, patients with CAG

13652826, 2023, 8, Downloaded from https://onlinelibrary.wiley.com/doi/10.1111/jne.13306, Wiley Online Library on [13/08/2025]. See the Terms and Conditions (https://onlinelibrary.wiley.com/terms-and-conditions) on Wiley Online Library for rules of use; OA articles are governed by the applicable Creative Commons License

carry a relevant risk of developing gastric adenocarcinoma. Although only one international guideline recommends a regular endoscopic follow-up for patients with CAG, the yearly rate of adenocarcinoma detection is up to 1% in patients with type I gNETs.[14] Whether this reflects an increased risk of adenocarcinoma development in patients with a previous diagnosis of gNET is not clear. For CAG patients without a gNET, intestinal metaplasia and *H. pylori* infection have been linked to an increased risk of adenocarcinoma progression. Given the high risk of adenocarcinoma detection upon follow-up of gNETs, this supports the recommendation to perform an endoscopic follow-up every 12–24 months in patients with previously diagnosed gNETs (specific timing may be proposed according to tumour size and histological features), whereas a 3-year interval is recommended in CAG patients without gNETs.[22]

Recommendations

1. An endoscopic follow-up by OGD is recommended 12 months after complete endoscopic resection of type I gNET (2b-B).
2. In those not requiring resection first follow-up should be 12 months and then consider annual to every 1–2 years (2b-B).
3. In patients with type I gNET, endoscopic follow-up by OGD is recommended also given the risk of developing gastric adenocarcinoma related to CAG (2b-A).

1.3.5 | Q4 – When is surgery recommended for type I gNETs?

Although type I gNETs are usually treated by an endoscopic approach, upfront surgical resection is recommended in all tumours that are greater than 20 mm in size or with suspected muscolaris propria invasion (either on axial imaging or EUS). In addition, surgery could be considered in tumours showing high risk features on biopsy (e.g., high grade 2 NET [cutoff not established], lymphovascular invasion). A limited resection with sampling of local lymph nodes is the preferred approach. Total gastrectomy with D2 lymphadenectomy should be discussed in patients with known lymph node metastases or might be proposed as a completion procedure after final histology has proven lymphatic spread, although there are no solid data supporting this option.

Endoscopic resection should not be attempted in the presence of invasion into the muscularis propria, suspected lymph node metastases or high-risk features of metastatic spread (e.g., high Ki-67, vascular invasion, size >20 mm). These patients should receive full staging including cross-sectional imaging as described previously and ^{68}Ga-SSA-PET-CT and upfront surgical management. The optimal cutoff value for Ki-67 is not determined, but Ki-67 values above 10% should trigger evaluation of surgical treatment. In the rare instance of a G3 type I gNET a primarily surgical approach is recommended due to high risk of metastases.[23] Regarding tumour size, no clear cutoff for surgical management can be defined. Only limited data exist on tumour size and risk of metastases in the subgroup of type I gNETs. Data from the SEER database and from a large series from Taiwan showed that a cutoff of 20 mm was associated with an increased risk of lymph node metastases.[13,24]

In case of incomplete endoscopic resection (R1) or risk features in final pathology after endoscopic resection, a surgical approach should be discussed with the patient to achieve R0 resection and/or resection of local lymph nodes to exclude metastatic spread. In cases of lesions not amenable to an endoscopic approach (e.g., location close to cardia) a primary surgical resection might be necessary.

SSA treatment to reduce gastrin production, thus diminishing the stimulus for further tumour growth and progression, could be proposed in patients who could not undergo resection or for multiple larger tumours or frequent relapse. Antrectomy should no longer be routinely offered but might be an option in patients not tolerating SSA or declining continuous application.

Recommendations

1. Surgical approach is recommended in tumours >20 mm or with suspected muscolaris propria invasion (either on axial imaging or EUS). In addition, surgery could be considered (in tumours showing high risk features on biopsies (high Ki-67, lymphovascular invasion) (2b-A).
2. Limited resection with local nodal sampling is the preferred surgical strategy (3b-A).
3. Gastrectomy with D2 lymphadenectomy (specific kind of resection according with the tumour site) should be discussed in patients with known lymph node metastases or might be proposed as a completion procedure after final histology has proven lymphatic spread after full exploration with cross sectional imaging (3b-A).

1.4 | Type II gNETs

Type II gNETs are the rarest type of gNET (5% of cases). They arise in the context of hypergastrinaemia associated with ZES which may occur in patients with MEN-I. Treatment of patients with type II gNETs strictly depends on the management of the MEN-I syndrome.[25]

1.5 | Management strategy for type III gNETS

1.5.1 | Background

Type III gNETs have been traditionally regarded as highly aggressive tumours requiring extended surgical resections (i.e., partial or total gastrectomy) with lymphadenectomy. However, with the widespread use of high-definition endoscopy, type III gNETs of smaller size and lower grade are increasingly being detected. A recent systematic review of 147 type III gNENs in which tumour management was reported found that ~45% were G1, 35% were G2 and 20% were G3.[26] As a result, less invasive treatment options, ranging from endoscopic resection to surgical wedge resection, have been investigated

13652826, 2023, 8, Downloaded from https://onlinelibrary.wiley.com/doi/10.1111/jne.13306, Wiley Online Library on [13/08/2025]. See the Terms and Conditions (https://onlinelibrary.wiley.com/terms-and-conditions) on Wiley Online Library for rules of use; OA articles are governed by the applicable Creative Commons License

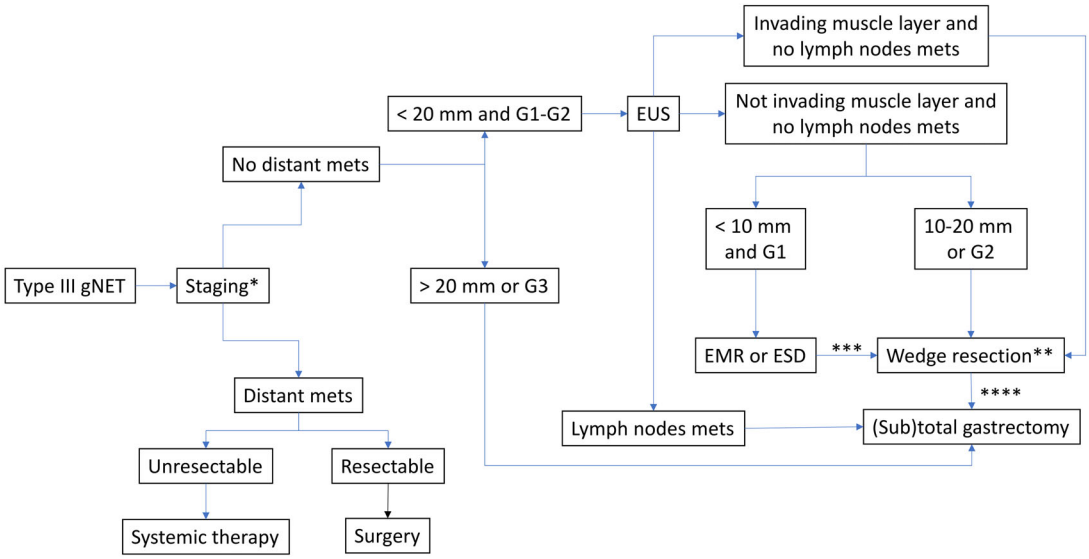

* Staging with cross-sectional and functional imagings required. ** With nodal sampling. *** If R1 after endoscopic resection. **** If N1 after wedge resection

FIGURE 2 Management of type III gastric neuroendocrine tumours (gNETs).

in highly selected patients. The management of type III gNETs is summarised in Figure 2.

1.5.2 | Q5 – Can endoscopic treatments be proposed to treat type III gNETs?

Type III gNETs should be carefully characterised using endoscopy, biopsy, cross sectional thoracoabdominal CT and liver MRI, and often functional imaging (^{68}Ga-SSA-PET-CT or FDG/PET-CT depending on tumour grade) and in most cases EUS. Evidence from several retrospective case series suggests that carefully selected patients who have no evidence of lymph node involvement can be safely and successfully managed by endoscopic resection. Endoscopic resection appears to be most appropriate in patients who have localised G1 tumours ≤10 mm in diameter, because tumours greater than this size are more likely to have lymph node metastases (even though these may not be detected by imaging techniques).[26,27] However endoscopic resection can also be considered in patients with slightly larger tumours (<15 mm) and low G2 (Ki-67 3–10%) histology, particularly if the risks of surgical resection are considered to be high.[26] Current evidence does not support the use of a particular endoscopic resection technique (EMR vs. ESD).[26] Some very small (<5 mm) tumours have also been unintentionally removed by avulsion biopsy with no evidence of subsequent tumour recurrence, but this approach is not generally recommended.[26] Patients with positive resection margins (R1) should be considered for additional endoscopic resection or surgical salvage if appropriate. Patients who have undergone endoscopic resection should have close follow up with endoscopy and imaging (thoracoabdominal CT and liver MRI) to detect local and distant tumour recurrence.

Recommendations

1. Endoscopic resection may be considered in patients who have localised type III G1 gNETs ≤10 mm, and occasionally larger tumours with Ki-67 <10% and <15 mm in diameter if the risks of surgical resection are high provided adequate staging is allowed (3a–C).

1.5.3 | Q6 – When should limited or extended surgical treatments be proposed to treat type III gNETs?

Several clinicopathological features should be carefully evaluated to identify the best surgical option (limited vs. extended resection) for patients with type III gNETs.

A limited gastric wedge resection without standard lymphadenectomy can be considered as treatment option in patients with localised, G1 type III gNETs with no evidence of lymph node involvement on preoperative imaging (including EUS).[26] In patients fulfilling the above-mentioned criteria, tumour size, depth of infiltration and presence of lymphovascular invasion should be further assessed to define the extent of surgical resection. Therefore, a wedge resection can be safely proposed to patients with G1 type III gNETs <20 mm, limited to the submucosal layer and with no evidence of lymphovascular invasion.[26,28] The role of wedge resections in patients with G2 type III gNETs remains debated, as tumour grade represents a powerful predictor of disease aggressiveness. Similarly, the tumour size cutoff for proposing limited surgical resection is not clearly defined. Type III gNETs <10 mm are usually managed with endoscopic resection, whereas a limited surgical resection might be considered as initial treatment option for lesions measuring >10 mm and <20 mm.[26] Recent experiences report favourable

13652826, 2023, 8, Downloaded from https://onlinelibrary.wiley.com/doi/10.1111/jne.13306, Wiley Online Library on [13/08/2025]. See the Terms and Conditions (https://onlinelibrary.wiley.com/terms-and-conditions) on Wiley Online Library for rules of use; OA articles are governed by the applicable Creative Commons License

oncological outcomes after endoscopic resection/limited surgical resection, thus strengthening the notion that a conservative approach might be appropriate for highly selected patients with type III gNETs.[27,29] In the presence of positive margins (R1) after endoscopic resection, salvage surgical wedge resection represents a possible treatment strategy.

Radical surgical resection, either total or subtotal gastrectomy, with lymphadenectomy represents the procedure of choice for all the patients diagnosed with type III gNETs showing at least one of the following features: (1) nodal or distant metastases on preoperative imaging, (2) Ki-67 proliferative index defining a G3 tumour (Ki-67 >20%), and (3) tumour size >20 mm. Radical surgery is recommended as second-line treatment when final histology reveals one or more of the following findings: presence of nodal metastases, higher tumour grade compared with original biopsy, lymphovascular invasion or lack of complete tumour clearance (R1), in patients initially managed with a limited wedge resection.[26]

Recommendations

1. A limited wedge resection with local nodal sampling (without standard lymphadenectomy) can be considered as a treatment option in patients with localised, G1–G2 type III gNETs, with no evidence of lymphadenopathy on full staging preoperative imaging (including EUS) (2b-B).
2. Radical surgical resection with lymphadenectomy is recommended in type III gNETs when nodal metastases are found/suspected on preoperative staging, if Ki67 >20% or tumour diameter >20 mm (2b-B).

1.5.4 | Q7 – What scheduled follow-up is recommended after endoscopic/surgical resection of type III gNETs?

Follow-up of patients who underwent surgical resection of type III gNETs is based on contrast-enhanced cross-sectional imaging (thoracoabdominal CT/liver-MRI with sometimes OGD and/or EUS or functional imaging [^{68}Ga-SSA-PET-CT and/or FDG-PET/CT depending on the tumour grade]). The timing of follow-up has never been clearly defined. When a total gastrectomy with lymphadenectomy is performed, the follow-up schedule adopted for gastric adenocarcinoma should be applied.[26] On the other hand, patients managed conservatively (endoscopic or surgical local excision) should undergo OGD after about 3 months to check the resection site and if this shows no macroscopic residual tumour, they should have regular follow-up with cross-sectional imaging and endoscopy/EUS. The frequency and choice of test will be influenced by the final tumour size and grade as well as patient fitness and in most cases, it will be possible to reduce the frequency of follow up as time progresses after resection. ^{68}Ga-SSA-PET-CT (or FDG-PET/CT depending on the tumour grade) and biopsies should be performed in the presence of a suspected disease relapse, but they are not routinely part of the follow-up programme.[30]

Recommendations

1. Radiological follow-up by contrast-enhanced CT or MRI is recommended in patients treated by surgical resection for type III gNETs (5-A).

2 | DUODENAL NEUROENDOCRINE TUMOURS

2.1 | Introduction – general background

Like gNETs, duodenal neuroendocrine tumours (dNETs) are rare tumours but also with an increasing incidence found mostly at OGD or axial imaging for other reasons (incidental discovery) but also can be found as primaries at workup for patients with stage 4 diseases or more rarely as part of inherited syndromes such as MEN-I and neurofibromatosis type 1 (NF1). Most dNETs are non-functional tumours, but duodenal tumours secreting gastrin are not infrequent (either sporadic or as part of MEN-I) and more rarely tumours secreting somatostatin (so called somatostatinomas) (see Guidance paper on functional pancreatic NETs).

The overall incidence of dNETs is low accounting for only 2.8% of all NETs.[31,32] The annual age adjusted incidence for dNET has been reported to be 0.19 per 100,000.[32] Traditionally, dNETs have been classified into non-functioning (approximately 90% of lesions) or functioning tumours (those secreting specific peptides of hormones eliciting a functional clinical consequence or syndrome)[33] and can be summarised as:

1. Non-functioning dNETs (they can secrete peptides and substances not resulting in a clinical condition or syndrome).
2. Duodenal composite gangliocytoma/neuroma and neuroendocrine tumour (CogNET) (previously known as gangliocytic paraganglioma), occurs almost exclusively in the second part of the duodenum and periampullary region and is considered a composite tumour of epithelial NETs and ganglioneuroma.[34]
3. Duodenal gastrinoma (gastrin secreting and either sporadic or part of MEN-I where duodenal localisation is very frequent) and somatostatinomas (not discussed in the present paper, see guidance paper on functioning pancreatic NETs).
4. Duodenal NEC (not discussed in the present paper, see guidance paper for digestive neuroendocrine carcinomas[35]).

2.2 | Assessment of dNETs

2.2.1 | Pathology

Pathological assessment and grading of dNETs is like that of NETs of all other sites. Adequate sampling is needed and the deep mucosal location of these lesions, usually suspected by the endoscopist due to the smooth surface as opposed to the more common adenomas and carcinomas of the duodenum, warrants an attempt to perform deep biopsies. Morphologically, the main differential diagnosis in the duodenum is the CoGNET, previously classified as a ganglioneuroma or paraganglioma, but now shown to be more similar to NETs.[36,37]

In cases with a high proliferation rate (i.e., mitotic count >20 in 2 mm^2 and/or Ki-67 index >20%), NEC and adenocarcinoma with

13652826, 2023, 8, Downloaded from https://onlinelibrary.wiley.com/doi/10.1111/jne.13306, Wiley Online Library on [13/08/2025]. See the Terms and Conditions (https://onlinelibrary.wiley.com/terms-and-conditions) on Wiley Online Library for rules of use; OA articles are governed by the applicable Creative Commons License

neuroendocrine features should be ruled out (see guidance paper for digestive neuroendocrine carcinomas[35]).

2.2.2 | Endoscopy

Most dNETs are in the first or second part of the duodenum.[38] Symptoms range from mostly none at incidental discovery to symptoms attributed to gastric outlet obstruction (in rare cases of large lesions) or anaemia. Patients with dNETs close to the ampulla and CoGNET which occur in the periampullary region can present with gastrointestinal bleeding, abdominal pain, anaemia or jaundice.[38,39] Periampullary dNETs are not infrequent in patients with neurofibromatosis type 1 (NF1), also known as Von Recklinghausen's disease including somatostatinomas.[40,41]

At OGD, dNETs have similar features to gNETs but are typically single small sessile, erythematous or pale lesions in the duodenal cap, bulb or D1 to D2.[6] In recent years, increasingly smaller lesions have been detected, owing to the better mucosal visualisation with modern endoscopic tools. The reported mean size of dNETs varies between 7 mm and 1.5 cm.[42] Up to 10% of dNETs can occur as multiple tumours, which should prompt a diagnosis of MEN-I. It has been reported that approximately a quarter to a third of patients with dNETs and ZES, have undiagnosed MEN-I.[43,44]

Endoscopic characterisation of dNETs has been described by Borbath and colleagues.[6] Diagnosis is usually confirmed at endoscopic forceps biopsy (care as very small lesions may be almost completely excised at biopsy sampling and making future identification hard in case of R1 resection). Tumours of 1 cm or above should have accurate local staging by EUS as regional lymph node metastases occur in up to 40%–60% of cases, especially in duodenal gastrinomas.[43,45,46]

Recommendations

Evaluation of dNETs should always include:

1. Biopsies to confirm the diagnosis and to evaluate proliferative activity of the tumour (Ki-67 and/or mitotic count) for grading (2b-A).
2. Endoscopic assessment of dNETs should include tumour location to identify periampullary tumours (2b-A).
3. EUS is recommended in tumours >1 cm (3b-B).

2.2.3 | Imaging and laboratory examinations

Duodenal NETs are generally diagnosed by endoscopy and endoscopic ultrasound. Computed tomography after ingestion of water to fill stomach and duodenum, is recommended to help preoperative exploration. CT-enterography, MRI, ^{68}Ga-SSA-PET-CT and ^{18}F-DOPA-PET/CT are not sufficiently accurate for localisation of well-differentiated gastroduodenal primary tumours,[47–49] but these examinations are used to help staging of regional and distant metastases.[50]

Laboratory tests are required for patients newly diagnosed with dNET. It is especially important to recognise potential gastrinoma (serum gastrin, chromogranin and occasionally secretin testing). Other laboratory tests, if symptoms are suggestive, may include somatostatin, and very rarely growth hormone releasing factor and cortisol with urinary 5-hydoxyindoleacetic acid.[38] If a diagnosis of genetic syndrome is suspected (e.g., MEN-I or NF1) specific laboratory tests and germline testing is advised[38,51] Distinguishing between dNET and neurofibromas may be difficult in some cases especially on axial imaging.

Recommendations

1. Locoregional and distant staging examiner actions for dNETs include contrast-enhanced CT (with water ingestion), liver -MRI and 68Ga-SSA-PET-CT (3b-B).
2. Ruling out gastrinoma and screening for genetic syndromes when appropriate should be considered for dNETs (3b-B).

2.3 | Management strategy for dNETs

Factors that need to be considered prior to endoscopic resection of dNET are:

1. Size of tumour (commonly estimated at EUS and OGD).
2. Depth of invasion in relation to the deep muscle layer (estimated at EUS).
3. Any evidence of lymphadenopathy and/or metastatic spread on EUS, liver-MRI, thoracoabdominal CT and functional imaging, preferably ^{68}Ga-SSA-PET-CT.
4. Grade and morphology of tumour (determined by endoscopy, EUS and endoscopic biopsy).
5. Endoscopic appearance: central depression/ulceration implies invasion.
6. Suitability for endoscopic resection: size of lesion/endoscopic access/location of lesion/proximity to ampulla.
7. Hormone secretion status.
8. Patient age and performance status.

Size of the lesion is not a definitive guide to the correct treatment. Treatment options are: endoscopic surveillance, endoscopic resection (by EMR/ESD/underwater EMR/over the scope clip), local duodenal resection (LR) or pancreatoduodenectomy (PD). The outcomes may be related to the factors of the tumour at presentation rather than the type of resection procedure.[52] The management of dNETs is summarised in Figure 3.

When defining surgical indications for dNET, several key points should be considered (see section 8.3).

2.3.1 | Q8 – When is endoscopic resection indicated?

Very small non-functioning lesions 5 mm or less in D1 are commonly removed after lifting injection and snare (or by diagnostic biopsy) before any histological diagnosis is made and these lesions do not usually recur or metastasise.

13652826, 2023, 8, Downloaded from https://onlinelibrary.wiley.com/doi/10.1111/jne.13306, Wiley Online Library on [13/08/2025]. See the Terms and Conditions (https://onlinelibrary.wiley.com/terms-and-conditions) on Wiley Online Library for rules of use; OA articles are governed by the applicable Creative Commons License

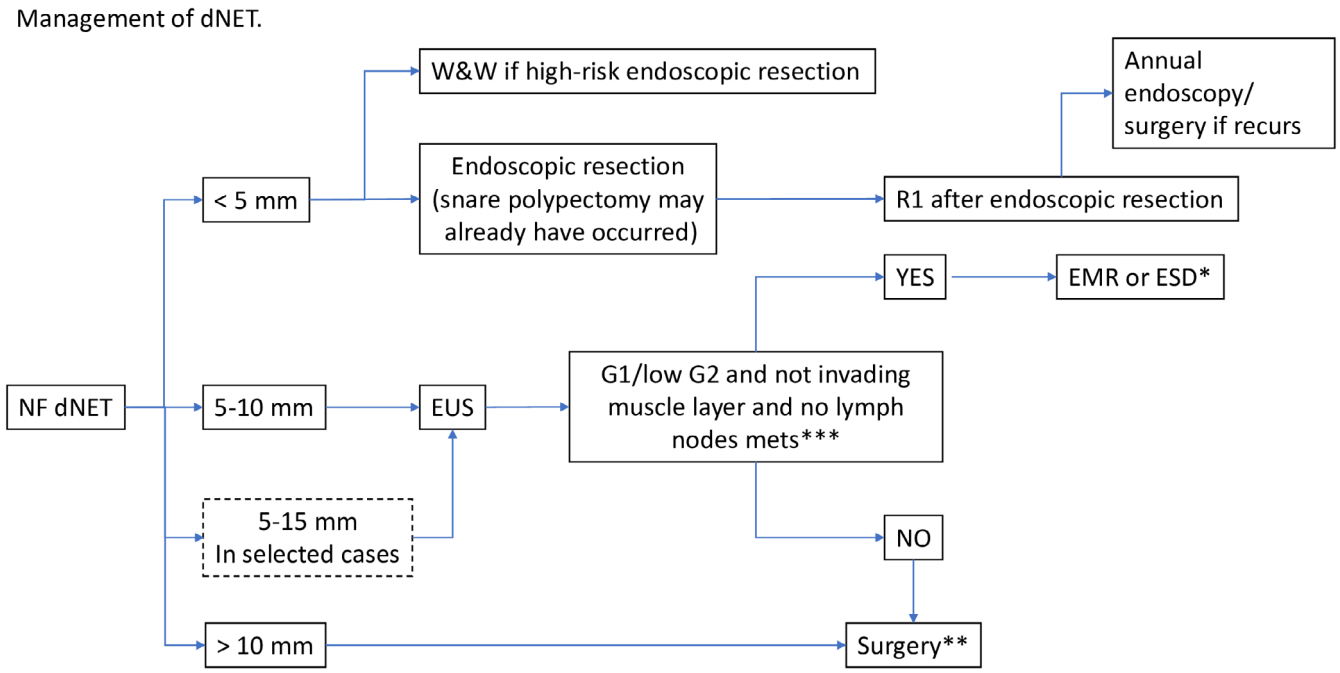

* ESD: only in centers with specific experience in advanced endoscopy (consider the high risk of duodenal perforation)
** Pre-operative staging with cross-sectional and functional imagings required.
***Endoscopic appearances of ulceration/ rolled edges may also indicate risk of invasion
W&W: watch and wait endoscopic surveillance; EMR: endoscopic mucosal resection; ESD: endoscopic submucosal dissection

FIGURE 3 Management of duodenal neuroendocrine tumours (dNETs).

For younger and fitter patients who have lesions of 5–10 mm (and up to 15 mm in some centres), an opinion should be sought from therapeutic endoscopy about resection and the associated risks. EUS should be performed as well as axial and functional imaging. Most of these lesions are grade 1 and not invading the muscle layer. In these circumstances an endoscopic resection using EMR/Cap EMR/ESD is reasonable, but risks of perforation are significant, especially in D2. If endoscopic therapy is high risk (published rates of perforation 15%–25%) or unlikely to be curative, LR (i.e., duodenotomy with tumour excision or enucleation) or pancreatoduodenectomy (PD) (if considered essential by the surgeon) should be considered. Endoscopic therapy combined with laparoscopy for rescue in the event of perforation has been performed which may represent a novel and valuable alternative to ESD, able to guarantee a high R0 rate and a low risk of intraoperative duodenal perforation.[53]

Duodenal NETs can be multiple, particularly if they are gastrinomas, and an association with MEN-I exists. Somatostatinomas can also occur in the duodenum, often close to the ampulla, but generally are without a clinical syndrome. There is an association with NF1 (functioning tumours are being addressed in a separate guidance paper on pancreatic functional NETs).

Recommendations

1. Very small non-functioning tumours in D1 should be removed using EMR type techniques (3b-C).
2. Lesions of 5–10 mm (and up to 15 mm in some centres) can be removed endoscopically after imaging work-up, but risks are relatively high (3b-C).

2.3.2 | Q9 – Can a "watch and wait" strategy be proposed in dNETs?

A watch and wait policy could be considered for very small (<5 mm) dNETs that cannot easily be resected, are non-functional, G1 and not invading the muscularis propria. This policy has usually been applied in patients unfit for endoscopic resection or surgery, since a more definitive therapy would be recommended in most cases, although a watch and wait policy has more recently been recommended as a result from some small series with limited follow-up. It is not clear if watch and wait is a suitable option in a patient who is fit for resection.[54,55]

Recommendations

There is very limited evidence for a watch and wait policy and generally this is applied to those unfit for surgery or endoscopic resection (3b-C).

2.3.3 | Q10 – When is surgery indicated?

Data on nodal risk in very small non-functioning dNETs are scarce. Some series report nodal metastases as a common finding in patients with dNET (40%–60%), with tumour size being the most relevant risk

13652826, 2023, 8, Downloaded from https://onlinelibrary.wiley.com/doi/10.1111/jne.13306, Wiley Online Library on [13/08/2025]. See the Terms and Conditions (https://onlinelibrary.wiley.com/terms-and-conditions) on Wiley Online Library for rules of use; OA articles are governed by the applicable Creative Commons License

factor for nodal involvement.[56] In cases with a tumour diameter >1 cm, nodal metastases were found in 13 out of 18 cases. Tumour location may be another important feature to be considered when defining surgical indication. Lesions arising in the ampullary/periampullary area differ from other dNETs due to a more aggressive biological behaviour in some studies[57] but not in others.[56] Functioning neoplasms harbour a higher metastatic potential.[58] Tumour invasion beyond the submucosa, tumour grade G2–G3 and lymphovascular invasion are factors affecting the risk of nodal metastases.

Despite very low grade evidence surgical resection may be indicated in patients with dNETs showing any of the following features:

1. Tumour size >10 mm; (some centres may advocate endoscopic removal in 10–15 mm).
2. Tumour extending beyond the submucosa.
3. Tumour grade G2–G3.
4. Lymphovascular invasion.
5. Functioning neoplasms.

Regarding the extent of resection, PD (pancreatoduodenectomy) and LR (local resection) represent the two main alternatives:

In general, pancreatoduodenectomy with lymphadenectomy is the procedure of choice for ampullary/periampullary neoplasms, due to their particular aggressiveness. When nodal metastases are pre- or intraoperatively identified, PD with nodal dissection is indicated in order to obtain a proper oncological clearance. However, for lesions <20 mm, less aggressive approaches (i.e., local excision with lymphadenectomy or pancreas-sparing total duodenectomy) may be considered options. At least eight lymph nodes should be harvested to stage patients accurately.[59] However, radical surgery is associated with a high rate of short- and long-term complications. Therefore, when feasible from an oncological perspective, other surgical strategies should be considered.

Local duodenal resection (i.e., duodenotomy with tumour excision or enucleation) represents a valuable and safe option, especially for patients with non-ampullary, non-functioning, dNET and without suspected nodal involvement at staging,[52] (where endoscopic resection is not possible). The role of nodal dissection in this setting is unclear as recent experience does not support the clearance of occult nodal metastases due to lack of association with survival advantages.[60]

Recommendations. 1. Surgery is recommended in cases of size >10–15 mm and/or tumour extending beyond the submucosa and/or grade G2-G3 and/or lymphovascular invasion (3-B).

3 | MANAGEMENT STRATEGY FOR GASTRIC AND DUODENAL G2–G3 METASTATIC NETS

3.1 | Treatment with curative intent

Due to the lack of effective systemic therapeutic options surgery should be evaluated even in the presence of metastatic condition depending on the tumour spread and tumour biology if a complete tumour resection seems to be possible (R0-resection).

Gastrectomy with D2-lymphadenectomy includes the removal of locoregional lymph nodes, so the presence of locoregional lymph node metastases should not preclude surgery as a treatment option. In dNET a transduodenal tumour excision with lymph node sampling or pancreatoduodenectomy are the treatments of choice.[30] The complete resection of single or multiple liver metastases might be beneficial even for G3 tumours.[61] Thus, surgical resection should be evaluated in G2 and in very selected cases of G3-NET depending on the general health condition of the patient. Single or multiple metastases in other locations should be evaluated for a complete resection.

3.2 | Widespread metastatic disease

In the presence of metastases, a systemic therapeutic approach is similar to that recommended for advanced/unresectable NET from other primary sites, owing to the lack of available data in homogeneous series of gastric or duodenal NETs. Somatostatin analogues are indicated for NETs G1–G2 with low Ki67 (<10%), and positive somatostatin receptors but can be administered in tumours with higher Ki-67 if slow tumour growth or slow progression are seen. Peptide receptor radionuclide therapy (PRRT) is a valid option depending on the receptor status of the tumour. Molecular-targeted therapy with everolimus is a therapeutic option, but with limited evidence.[62] In NET G3 chemotherapy should be administered.[63]

3.3 | Palliative primary tumour resection

In cases of unresectable distant metastases a palliative primary tumour resection can be considered rarely to avoid local complications. The kind and extent of surgery has to be evaluated depending on the location of the tumour and possibility of complications of surgery. A gastrectomy can be necessary in rare cases but a wedge resection, distal or subtotal gastric resection should be preferred to reduce perioperative morbidity. A gastric bypass without tumour resection should be favoured in case of bulky disease with infiltration of the visceral arteries or pancreas.

3.4 | Local recurrence

In the presence of local recurrence without diffuse metastatic spread, operative resection should be favoured to avoid bleeding or intestinal obstruction and to maintain quality of life. Even in the presence of distant metastatic spread palliative surgery should be considered to ensure quality of life depending on the tumour biology and the general health status of the patient. Endoscopic procedures such as stent or jejunal catheterisation are alternatives for patients with a poor general health status.

13652826, 2023, 8, Downloaded from https://onlinelibrary.wiley.com/doi/10.1111/jne.13306, Wiley Online Library on [13/08/2025]. See the Terms and Conditions (https://onlinelibrary.wiley.com/terms-and-conditions) on Wiley Online Library for rules of use; OA articles are governed by the applicable Creative Commons License

3.5 | Follow-up

The interval for follow-up by contrast-enhanced thoracoabdominal CT and/or liver-MRI, 3–12 months, should be based on the malignant potential of the tumour.[64] Follow-up by additional ^{68}Ga-SSA-PET-CT is helpful when the patient's clinical status and the results of CT or MRI and biochemistry are discordant. The sensitivity of ^{68}Ga-SSA-PET-CT is superior to contrast-enhanced thoracoabdominal CT for characterisation and detection of lymph node metastases and for visualisation of metastases to bone and liver,[65] and therefore provides earlier detection of new lesions. FDG-PET/CT is instead used in G3 tumours and can also be helpful in high G2 NET when ^{68}Ga-SSA-PET-CT is negative. Re-evaluation of untreated patients should be performed at 3–6 month intervals.

Recommendations

1. Surgery with curative intention of metastatic gastroduodenal NET G1/G2/G3 should be performed, if a complete tumour (including metastases) resection seems feasible (4-B).

2. Palliative surgery (primary resection, bypass) may be indicated in metastatic disease to maintain quality of life (4-C).
3. The choice of systemic therapy for metastatic gastroduodenal NET depends on tumour grading and includes biotherapy, everolimus, PRRT and chemotherapy (4-B).

4 | CONCLUSIONS

4.1 | Gastric NETs

1. Evaluation of the type of gNETs by assessing separate biopsies from the antral and fundic mucosa is needed.
2. Endoscopic resection should be proposed in type I gNETs larger than 1 cm, whereas a surgical approach should be proposed in tumours larger than 2 cm. Tumours between 1 cm and 2 cm in size are usually managed by endoscopic resection after EUS evaluation, although surgery might be indicated in selected cases with G2 tumours and high Ki-67 (cutoff not established), and in G3 tumours.
3. In type III gNETs, a surgical approach is recommended. However, in selected patients with small (<1 cm) G1 tumours, endoscopic resection may be appropriate.

4.2 | Duodenal NETs

1. Endoscopic assessment should include tumour location to identify periampullary tumours. EUS is recommended in tumours >1 cm.
2. Very small non-functioning tumours in D1 may be removed using EMR type techniques, whereas larger tumours (>1 cm) and/or tumour extending beyond the submucosa and/or grades G2–G3 and/or lymphovascular invasion and/or functioning neoplasms should be managed by a surgical approach after complete disease staging by dedicated CT, liver-MRI+/− ^{68}Ga-SSA-PET-CT.

4.3 | Unmet needs

1. The prognostic role of Ki67 in type I gNETs is unclear.
2. Long-term outcomes of endoscopic resection for both selected gastric type 3 NETs, and also duodenal NETs, are lacking.
3. The risk of progression in low-grade gastroduodenal NETs after incomplete R1 endoscopic resection is unknown.
4. The role of somatostatin analogue treatments in managing type I gNETs has not yet been established.
5. More data are required regarding natural history PPI-induced gNETs.

AUTHOR CONTRIBUTIONS

Francesco Panzuto: Conceptualization; methodology; supervision; writing – original draft; writing – review and editing. **John Ramage:** Conceptualization; writing – original draft; writing – review and editing. **Mark Pritchard:** Conceptualization; writing – original draft; writing – review and editing. **Marie-Louise van Velthuysen:** Conceptualization; writing – original draft; writing – review and editing. **Jörg Schrader:** Conceptualization; writing – original draft; writing – review and editing. **Nehara Begum:** Conceptualization; writing – original draft; writing – review and editing. **Anders Sundin:** Conceptualization; writing – original draft; writing – review and editing. **Massimo Falconi:** Conceptualization; writing – original draft; writing – review and editing. **Dermot O'Toole:** Conceptualization; methodology; supervision; writing – original draft; writing – review and editing.

ACKNOWLEDGEMENTS

Participants of the ENETS Guidance Paper Consensus Meeting – 13 October 2022. Bartsch, D. K. (Department of Visceral-, Thoracic- and Vascular Surgery Philipps-University Marburg, Marburg, Germany); Capdevila, J. (Medical Oncology Department, Gastrointestinal and Endocrine Unit, Vall d'Hebron University Hospital, Barcelona, Spain); Caplin, M. (Neuroendocrine Tumour Unit, ENETS Centre of Excellence, Royal Free Hospital and University College London, London, UK); Castaño, J. P. (Maimonides Biomedical Research Institute of Córdoba (IMIBIC), Reina Sofia University Hospital, University of Córdoba, Córdoba, Spain); Couvelard, A. (Pathology Department, Bichat Hospital, AP-HP and Université Paris Cité, Paris, France); De Mestier L. (Beaujon Hospital, Université Paris-Cité, Pancreatology and Digestive Oncology, Paris, France); Denecke, T. (Klinik für Diagnostische und Interventionelle Radiologie, Universitätsklinikum Leipzig, Leipzig, Germany); Fazio, N. (Division of Gastrointestinal Medical Oncology and neuroendocrine tumors, European Institute of Oncology (IEO), IRCCS, Milan, Italy); Garcia-Carbonero, R. (Department of Oncology, Hospital Universitario Doce de Octubre, Imas12, UCM,

13652826, 2023, 8, Downloaded from https://onlinelibrary.wiley.com/doi/10.1111/jne.13306, Wiley Online Library on [13/08/2025]. See the Terms and Conditions (https://onlinelibrary.wiley.com/terms-and-conditions) on Wiley Online Library for rules of use; OA articles are governed by the applicable Creative Commons License

Madrid, Spain); Hofland, J. (Department of Internal Medicine, Erasmus MC, Rotterdam, The Netherlands); Kaltsas, G. (1st Propaedeutic Department of Internal Medicine, National and Kapodistrian University of Athens, Athens, Greece); Kjaer, A. (Department of Clinical Physiology and Nuclear Medicine & Cluster for Molecular Imaging, Copenhagen University Hospital – Rigshospitalet & Department of Biomedical Sciences, University of Copenhagen, Copenhagen, Denmark); Knigge, U. (Departments of Surgery and Clinical Endocrinology, ENETS Centre of Excellence, Copenhagen University Hospital, Rigshospitalet, Copenhagen, Denmark); Koumarianou A. (National and Kapodistrian University of Athens, Haematology Oncology Unit, 4th Department of Internal Medicine, Athens, Greece); Pavel, M. (Department of Medicine 1, Universitätsklinikum Erlangen, Erlangen, Germany); Rindi, G. (Section of Anatomic Pathology, Department of Life Sciences and Public Health, Università Cattolica del Sacro Cuore/Unit of Head and Neck, Thoracic and Endocrine Pathology, Department of Woman and Child Health Sciences and Public Health, Fondazione Policlinico Universitario A. Gemelli IRCCS, Roma, Italia/Roma European Neuroendocrine Tumour Society (ENETS) Center of Excellence, Rome, Italy); Santos A. P. (Endocrinology Department, Endocrine Tumours Clinic, Precancerous Lesions and Early Cancer Management Group, RISE@CI-IPO (Health Research Network), Portuguese Oncology Institute of Porto (IPO Porto)/Porto Comprehensive Cancer Center (Porto.CCC), Porto, Portugal); Srirajaskanthan R. (Neuroendocrine Tumour Unit, Kings College Hospital/Department of Gastroenterology, Hambleden Wing, Kings College Hospital, London, UK); Tiensuu Janson, E. (Department of Medical Sciences, Endocrine Oncology, Medical Faculty, Uppsala Universitet, Uppsala, Sweden); Toumpanakis, C. (Neuroendocrine Tumour Unit, ENETS Centre of Excellence, Royal Free Hospital and University College London, London, UK); Walter, T. (Department of Medical Oncology, Hôpital Edouard Herriot, Lyon, France).

CONFLICT OF INTEREST STATEMENT

D. Mark Pritchard received funding for consultancy, lectures and conference attendance from Ipsen, Advanced Accelerator Applications and Mayoly Spindler laboratories and research funding to investigate the role of netazepide in type I gastric NETs from Trio Medicines Ltd. John Ramage received research funding from Novartis and Ipsen.

PEER REVIEW

The peer review history for this article is available at https://www.webofscience.com/api/gateway/wos/peer-review/10.1111/jne.13306.

DATA AVAILABILITY STATEMENT

not applicable given the study design (clinical guidelines).

ORCID

Francesco Panzuto https://orcid.org/0000-0003-2789-4289
John Ramage https://orcid.org/0000-0003-4824-6600
D. Mark Pritchard https://orcid.org/0000-0001-7971-3561
Marie-Louise F. van Velthuysen https://orcid.org/0000-0003-0435-9494
Anders Sundin https://orcid.org/0000-0002-2214-6217

REFERENCES

1. Dasari A, Shen C, Halperin D, et al. Trends in the incidence, prevalence, and survival outcomes in patients with neuroendocrine tumors in the United States. *JAMA Oncol*. 2017;3(10):1335-1342. doi:10.1001/jamaoncol.2017.0589
2. Rindi G, Luinetti O, Cornaggia M, Capella C, Solcia E. Three subtypes of gastric argyrophil carcinoid and the gastric neuroendocrine carcinoma: a clinicopathologic study. *Gastroenterology*. 1993;104(4):994-1006. doi:10.1016/0016-5085(93)90266-f
3. Sato Y, Iwafuchi M, Ueki J, et al. Gastric carcinoid tumors without autoimmune gastritis in Japan: a relationship with *Helicobacter pylori* infection. *Dig Dis Sci*. 2002;47(3):579-585.
4. Fossmark R, Calvete O, Mjønes P, Benitez J, Waldum HL. ECL-cell carcinoids and carcinoma in patients homozygous for an inactivating mutation in the gastric H(+) K(+) ATPase alpha subunit. *APMIS*. 2016;124(7):561-566. doi:10.1111/apm.12546
5. Trinh VQ, Shi C, Ma C. Gastric neuroendocrine tumours from long-term proton pump inhibitor users are indolent tumours with good prognosis. *Histopathology*. 2020;77(6):865-876. doi:10.1111/his.14220
6. Borbath I, Pape UF, Deprez PH, et al. ENETS standardized (synoptic) reporting for endoscopy in neuroendocrine tumors. *J Neuroendocrinol*. 2022;34(3):e13105. doi:10.1111/jne.13105
7. La Rosa S, Vanoli A. Gastric neuroendocrine neoplasms. In: Fukayama M, Rugge M, Washington M, eds. *Digestive System Tumours. WHO Classification of Tumours, Vol. 1*. IARC Press; 2019:104-109.
8. Rindi G, Klimstra DS, Abedi-Ardekani B, et al. A common classification framework for neuroendocrine neoplasms: an International Agency for Research on Cancer (IARC) and World Health Organization (WHO) expert consensus proposal. *Mod Pathol*. 2018;31(12):1770-1786. doi:10.1038/s41379-018-0110-y
9. Esposito G, Angeletti S, Cazzato M, et al. Narrow band imaging characteristics of gastric polypoid lesions: a single-center prospective pilot study. *Eur J Gastroenterol Hepatol*. 2020 Jun;32(6):701-705. doi:10.1097/MEG.0000000000001697
10. Rinzivillo M, Panzuto F, Esposito G, Lahner E, Signore A, Annibale B. Usefulness of 68-gallium PET in type I gastric neuroendocrine neoplasia: a case series. *J Clin Med*. 2022;11(6):1641. doi:10.3390/jcm11061641
11. Tsolakis AV, Ragkousi A, Vujasinovic M, Kaltsas G, Daskalakis K. Gastric neuroendocrine neoplasms type 1: a systematic review and meta-analysis. *World J Gastroenterol*. 2019;25(35):5376-5387. doi:10.3748/wjg.v25.i35.5376
12. Exarchou K, Hu H, Stephens NA, et al. Endoscopic surveillance alone is feasible and safe in type I gastric neuroendocrine neoplasms less than 10 mm in diameter. *Endocrine*. 2022 Oct;78(1):186-196. doi:10.1007/s12020-022-03143-3
13. Chung CS, Tsai CL, Chu YY, et al. Clinical features and outcomes of gastric neuroendocrine tumors after endoscopic diagnosis and treatment: a digestive endoscopy Society of Tawian (DEST). *Medicine (Baltimore)*. 2018;97(38):e12101. doi:10.1097/MD.0000000000012101
14. Chin JL, O'Connell J, Muldoon C, et al. Selective resection of type 1 gastric neuroendocrine neoplasms and the risk of progression in an endoscopic surveillance programme. *Dig Surg*. 2021;38(1):38-45. doi:10.1159/000510962
15. Panzuto F, Magi L, Esposito G, Rinzivillo M, Annibale B. Comparison of endoscopic techniques in the management of type I gastric neuroendocrine neoplasia: a systematic review. *Gastroenterol Res Pract*. 2021 Mar;30(2021):6679397-6. doi:10.1155/2021/6679397

13652826, 2023, 8, Downloaded from https://onlinelibrary.wiley.com/doi/10.1111/jne.13306, Wiley Online Library on [13/08/2025]. See the Terms and Conditions (https://onlinelibrary.wiley.com/terms-and-conditions) on Wiley Online Library for rules of use; OA articles are governed by the applicable Creative Commons License

16. Noh JH, Kim DH, Yoon H, et al. Clinical outcomes of endoscopic treatment for type 1 gastric neuroendocrine tumor. *J Gastrointest Surg*. 2021;25(10):2495-2502. doi:10.1007/s11605-021-04997-0
17. Sato Y, Takeuchi M, Hashimoto S, et al. Usefulness of endoscopic submucosal dissection for type I gastric carcinoid tumors compared with endoscopic mucosal resection. *Hepatogastroenterology*. 2013;60(126):1524-1529. doi:10.5754/hge121185
18. Pimentel-Nunes P, Libânio D, Bastiaansen BAJ, et al. Endoscopic submucosal dissection for superficial gastrointestinal lesions: European Society of Gastrointestinal Endoscopy (ESGE) guideline-update 2022. *Endoscopy*. 2022;54(6):591-622. doi:10.1055/a-1811-7025
19. Esposito G, Cazzato M, Rinzivillo M, et al. Management of type-I gastric neuroendocrine neoplasms: a 10-years prospective single Centre study. *Dig Liver Dis*. 2022;54(7):890-895. doi:10.1016/j.dld.2021.11.012
20. Rossi RE, Invernizzi P, Mazzaferro V, Massironi S. Response and relapse rates after treatment with long-acting somatostatin analogs in multifocal or recurrent type-1 gastric carcinoids: a systematic review and meta-analysis. *United European Gastroenterol J*. 2020;8(2):140-147. doi:10.1177/2050640619890465
21. Boyce M, Moore AR, Sagatun L, et al. Netazepide, a gastrin/cholecystokinin-2 receptor antagonist, can eradicate gastric neuroendocrine tumours in patients with autoimmune chronic atrophic gastritis. *Br J Clin Pharmacol*. 2017;83(3):466-475. doi:10.1111/bcp.13146
22. Pimentel-Nunes P, Libânio D, Marcos-Pinto R, et al. Management of epithelial precancerous conditions and lesions in the stomach (MAPS II): European Society of Gastrointestinal Endoscopy (ESGE), European helicobacter and microbiota study group (EHMSG), European Society of Pathology (ESP), and Sociedade Portuguesa de Endoscopia Digestiva (SPED) guideline update 2019. *Endoscopy*. 2019;51(4):365-388. doi:10.1055/a-0859-1883
23. Vanoli A, La Rosa S, Miceli E, et al. Prognostic evaluations tailored to specific gastric neuroendocrine neoplasms: analysis of 200 cases with extended follow-up. *Neuroendocrinology*. 2018;107(2):114-126. doi:10.1159/000489902
24. Ye H, Yuan Y, Chen P, Zheng Q. Risk factors for metastasis and survival of patients with T1 gastric neuroendocrine carcinoma treated with endoscopic therapy versus surgical resection. *Surg Endosc*. 2022;36(8):6162-6169. doi:10.1007/s00464-022-09190-1
25. Thakker RV, Newey PJ, Walls GV, et al. Clinical practice guidelines for multiple endocrine neoplasia type 1 (MEN1). *J Clin Endocrinol Metab*. 2012;97(9):2990-3011. doi:10.1210/jc.2012-1230
26. Exarchou K, Kamieniarz L, Tsoli M, et al. Is local excision sufficient in selected grade 1 or 2 type III gastric neuroendocrine neoplasms? *Endocrine*. 2021;74(2):421-429. doi:10.1007/s12020-021-02775-1
27. Hirasawa T, Yamamoto N, Sano T. Is endoscopic resection appropriate for type 3 gastric neuroendocrine tumors? Retrospective Multicenter Study. *Dig Endosc*. 2021;33(3):408-417. doi:10.1111/den.13778
28. Min BH, Hong M, Lee JH, et al. Clinicopathological features and outcome of type 3 gastric neuroendocrine tumours. *Br J Surg*. 2018;105(11):1480-1486. doi:10.1002/bjs.10901
29. Hanna A, Kim-Kiselak C, Tang R, et al. Gastric neuroendocrine tumors: reappraisal of type in predicting outcome. *Ann Surg Oncol*. 2021;28(13):8838-8846. doi:10.1245/s10434-021-10293-7
30. Sato Y, Hashimoto S, Mizuno K, Takeuchi M, Terai S. Management of gastric and duodenal neuroendocrine tumors. *World J Gastroenterol*. 2016;22(30):6817-6828. doi:10.3748/wjg.v22.i30.6817
31. Yao JC, Hassan M, Phan A, et al. One hundred years after "carcinoid": epidemiology of and prognostic factors for neuroendocrine tumors in 35,825 cases in the United States. *J Clin Oncol*. 2008;26(18):3063-3072. doi:10.1200/JCO.2007.15.4377
32. Fitzgerald TL, Dennis SO, Kachare SD, Vohra NA, Zervos EE. Increasing incidence of duodenal neuroendocrine tumors: incidental discovery of indolent disease? *Surgery*. 2015 Aug;158(2):466-471. doi:10.1016/j.surg.2015.03.042
33. Klöppel G, Perren A, Heitz PU. The gastroenteropancreatic neuroendocrine cell system and its tumors: the WHO classification. *Ann N Y Acad Sci*. 2004;1014:13-27. doi:10.1196/annals.1294.002
34. Rindi G, Mete O, Uccella S, et al. Overview of the 2022 WHO classification of neuroendocrine neoplasms. *Endocr Pathol*. 2022;33(1):115-154. doi:10.1007/s12022-022-09708-2
35. Sorbye H, Grande E, Pavel M, et al. European Neuroendocrine Tumor Society (ENETS) 2023 guidance paper for digestive neuroendocrine carcinoma. *J Neuroendocrinol*. 2023;35(3). doi:10.1111/jne.13249
36. WHO Classification of Tumours Editorial Board. *Endocrine and neuroendocrine tumours*. International Agency for Research on Cancer; 2022.
37. Mamilla D, Manukyan I, Fetsch PA, Pacak K, Miettinen M. Immunohistochemical distinction of paragangliomas from epithelial neuroendocrine tumors-gangliocytic duodenal and cauda equina paragangliomas align with epithelial neuroendocrine tumors. *Hum Pathol*. 2020;103:72-82. doi:10.1016/j.humpath.2020.07.010
38. Delle Fave G, Kwekkeboom DJ, Van Cutsem E, et al. Barcelona consensus conference participants. ENETS consensus guidelines for the management of patients with gastroduodenal neoplasms. *Neuroendocrinology*. 2012;95(2):74-87. doi:10.1159/000335595
39. Okubo Y, Yokose T, Motohashi O, et al. Duodenal rare neuroendocrine tumor: Clinicopathological characteristics of patients with Gangliocytic Paraganglioma. *Gastroenterol Res Pract*. 2016;2016:5257312. doi:10.1155/2016/5257312
40. Hoffmann KM, Furukawa M, Jensen RT. Duodenal neuroendocrine tumors: classification, functional syndromes, diagnosis and medical treatment. *Best Pract Res Clin Gastroenterol*. 2005;19(5):675-697. doi:10.1016/j.bpg.2005.05.009
41. Stamm B, Hedinger CE, Saremaslani P. Duodenal and ampullary carcinoid tumors. A report of 12 cases with pathological characteristics, polypeptide content and relation to the MEN I syndrome and von Recklinghausen's disease (neurofibromatosis). *Virchows Arch A Pathol Anat Histopathol*. 1986;408(5):475-489. doi:10.1007/BF00705301
42. Exarchou K, Moore AR, Smart HL, Duckworth CA, Howes N, Pritchard DM. A "watch and wait" strategy involving regular endoscopic surveillance is safe for many patients with small, sporadic, grade 1, non-ampullary, non-functioning duodenal neuroendocrine tumours. *Neuroendocrinology*. 2021;111(8):764-774. doi:10.1159/000511613
43. Benya RV, Metz DC, Venzon DJ, et al. Zollinger-Ellison syndrome can be the initial endocrine manifestation in patients with multiple endocrine neoplasia-type I. *Am J Med*. 1994;97(5):436-444. doi:10.1016/0002-9343(94)90323-9
44. Chin JL, O'Toole D. Diagnosis and management of upper gastrointestinal neuroendocrine tumors. *Clin Endosc*. 2017;50(6):520-529. doi:10.5946/ce.2017.181
45. Yu F, Venzon DJ, Serrano J, et al. Prospective study of the clinical course, prognostic factors, causes of death, and survival in patients with long-standing Zollinger-Ellison syndrome. *J Clin Oncol*. 1999;17(2):615-630. doi:10.1200/JCO.1999.17.2.615
46. Weber HC, Venzon DJ, Lin JT, et al. Determinants of metastatic rate and survival in patients with Zollinger-Ellison syndrome: a prospective long-term study. *Gastroenterology*. 1995;108(6):1637-1649. doi:10.1016/0016-5085(95)90124-8
47. Tsai SD, Kawamoto S, Wolfgang CL, Hruban RH, Fishman EK. Duodenal neuroendocrine tumors: retrospective evaluation of CT imaging features and pattern of metastatic disease on dual-phase MDCT with pathologic correlation. *Abdom Imaging*. 2015;40(5):1121-1130. doi:10.1007/s00261-014-0322-7
48. Imperiale A, Averous G, Helali M, et al. Limited role of carbidopa-assisted ^{18}F-FDOPA PET/CT in patients with sporadic non-functional gastroduodenal neuroendocrine neoplasms. *Ann Nucl Med*. 2019;33(9):697-707. doi:10.1007/s12149-019-01378-1

13652826, 2023, 8, Downloaded from https://onlinelibrary.wiley.com/doi/10.1111/jne.13306, Wiley Online Library on [13/08/2025]. See the Terms and Conditions (https://onlinelibrary.wiley.com/terms-and-conditions) on Wiley Online Library for rules of use; OA articles are governed by the applicable Creative Commons License

49. Sharma A, Das CJ, Makharia GK, Arora G, Kumar R. Comparison of contrast-enhanced CT + CT enterography and 68Ga-DOTANOC PET/CT in gastroenteropancreatic neuroendocrine tumors. *Clin Nucl Med*. 2020;45(11):848-853. doi:10.1097/RLU.0000000000003188
50. Sundin A, Arnold R, Baudin E, et al. ENETS consensus guidelines for the standards of care in neuroendocrine tumors: radiological, nuclear medicine & hybrid imaging. *Neuroendocrinology*. 2017;105(3):212-244. doi:10.1159/000471879
51. Niederle B, Selberherr A, Bartsch DK, et al. Multiple endocrine neoplasia type 1 and the pancreas: diagnosis and treatment of functioning and non-functioning pancreatic and duodenal neuroendocrine neoplasia within the MEN1 syndrome-an international consensus Statement. *Neuroendocrinology*. 2021;111(7):609-630. doi:10.1159/000511791
52. Margonis GA, Samaha M, Kim Y, et al. A multi-institutional analysis of duodenal neuroendocrine tumors: tumor biology rather than extent of resection dictates prognosis. *J Gastrointest Surg*. 2016;20(6):1098-1105. doi:10.1007/s11605-016-3135-x
53. Tsujimoto H, Ichikura T, Nagao S, et al. Minimally invasive surgery for resection of duodenal carcinoid tumors: endoscopic full-thickness resection under laparoscopic observation. *Surg Endosc*. 2010;24(2):471-475. doi:10.1007/s00464-009-0574-4
54. Mandair D, Kamieniarz L, Pizanias M, et al. Diagnostic features and management options for duodenal neuroendocrine neoplasms: a retrospective, multi-centre study. *Sci Rep*. 2022;12(1):15762. doi:10.1038/s41598-022-19738-9
55. Exarchou K, Howes N, Pritchard DM. Systematic review: management of localised low-grade upper gastrointestinal neuroendocrine tumours. *Aliment Pharmacol Ther*. 2020;51(12):1247-1267. doi:10.1111/apt.15765
56. Dogeas E, Cameron JL, Wolfgang CL, et al. Duodenal and ampullary carcinoid tumors: size predicts necessity for lymphadenectomy. *J Gastrointest Surg*. 2017 Aug;21(8):1262-1269. doi:10.1007/s11605-017-3448-4
57. Ruff SM, Standring O, Wu G, et al. Ampullary neuroendocrine tumors: insight into a rare histology. *Ann Surg Oncol*. 2021;28(13):8318-8328. doi:10.1245/s10434-021-10371-w
58. Massironi S, Campana D, Partelli S, et al. Heterogeneity of duodenal neuroendocrine tumors: an Italian multi-center experience. *Ann Surg Oncol*. 2018;25(11):3200-3206. doi:10.1245/s10434-018-6673-5
59. Zhang XF, Wu XN, Tsilimigras DI, et al. Duodenal neuroendocrine tumors: impact of tumor size and total number of lymph nodes examined. *J Surg Oncol*. 2019;120(8):1302-1310. doi:10.1002/jso.25753
60. Fujii Y, Tzeng CW, Chiang YJ, et al. Incidence of lymph node metastases and impact of radical surgery for duodenal neuroendocrine tumors. *J Surg Res*. 2021;268:419-431. doi:10.1016/j.jss.2021.06.085
61. Pommergaard HC, Nielsen K, Sorbye H, et al. Surgery of the primary tumour in 201 patients with high-grade gastroenteropancreatic neuroendocrine and mixed neuroendocrine-non-neuroendocrine neoplasms. *J Neuroendocrinol*. 2021;33(5):e12967. doi:10.1111/jne.12967
62. Yao JC, Fazio N, Singh S, et al. Everolimus for the treatment of advanced, non-functional neuroendocrine tumours of the lung or gastrointestinal tract (RADIANT-4): a randomised, placebo-controlled, phase 3 study. *Lancet*. 2016;387(10022):968-977. doi:10.1016/S0140-6736(15)00817-X
63. de Mestier L, Lamarca A, Hernando J, et al. Treatment outcomes of advanced digestive well-differentiated grade 3 NETs. *Endocr Relat Cancer*. 2021;28(8):549-561. doi:10.1530/ERC-21-0109
64. Janson ET, Knigge U, Dam G, et al. Nordic guidelines 2021 for diagnosis and treatment of gastroenteropancreatic neuroendocrine neoplasms. *Acta Oncol*. 2021;60(7):931-941. doi:10.1080/0284186X.2021.1921262
65. Johnbeck CB, Knigge U, Kjær A. PET tracers for somatostatin receptor imaging of neuroendocrine tumors: current status and review of the literature. *Future Oncol*. 2014;10(14):2259-2277. doi:10.2217/fon.14.139

SUPPORTING INFORMATION

Additional supporting information can be found online in the Supporting Information section at the end of this article.

How to cite this article: Panzuto F, Ramage J, Pritchard DM, et al. European Neuroendocrine Tumor Society (ENETS) 2023 guidance paper for gastroduodenal neuroendocrine tumours (NETs) G1–G3. *J Neuroendocrinol*. 2023;35(8):e13306. doi:10.1111/jne.13306

13652826, 2023, 8, Downloaded from https://onlinelibrary.wiley.com/doi/10.1111/jne.13306, Wiley Online Library on [13/08/2025]. See the Terms and Conditions (https://onlinelibrary.wiley.com/terms-and-conditions) on Wiley Online Library for rules of use; OA articles are governed by the applicable Creative Commons License